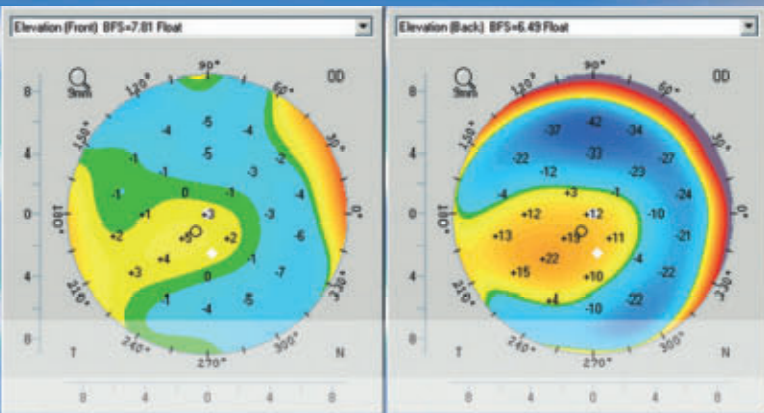
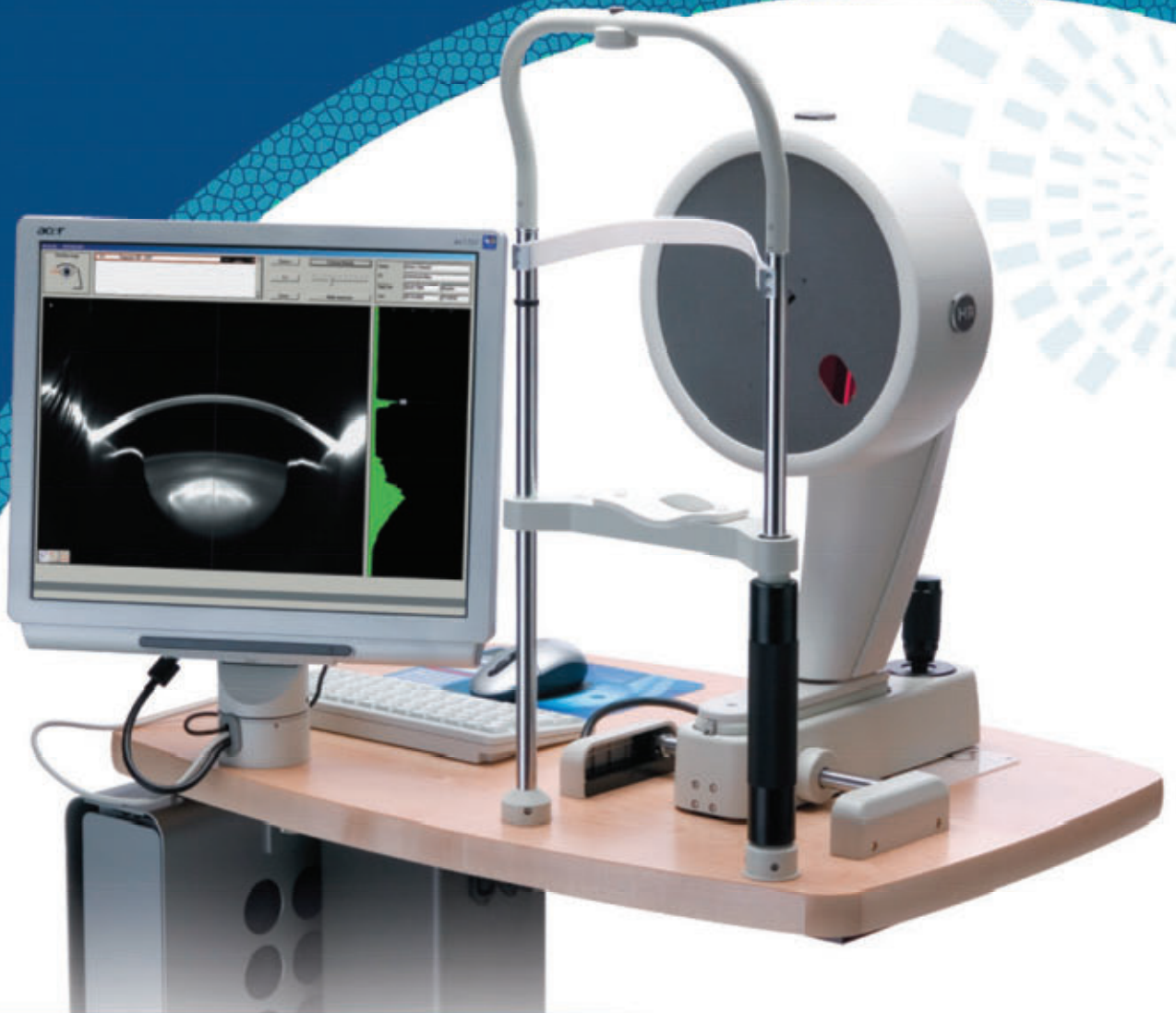

# NEW ADVANCES and TECHNOLOGY with PENTACAM



Keratoconus / Ectasia Detection  
with the Oculus Pentacam:  
Belin / Ambrósio  
Enhanced Ectasia Display

Application of Pentacam in Anterior Chamber  
Measurements for Phakic IOL Surgery

Holladay Report on the Pentacam



# Contents

- 3 Keratoconus / Ectasia Detection with the Oculus Pentacam:  
Belin / Ambrósio Enhanced Ectasia Display**  
Michael W. Belin, MD, FACS • Stephen S. Khachikian, MD
- 8 Application of Pentacam in Anterior Chamber Measurements  
for Phakic IOL Surgery**  
Mana Tehrani, MD
- 10 Holladay Report on the Pentacam**  
Jack T. Holladay, M.D., M.S.E.E., F.A.C.S

## Contributing Authors:

**Michael W. Belin, MD, FACS**

Professor & Director – Cornea & Refractive Surgery  
Albany Medical College Lions Eye Institute  
Albany, New York (USA)

**Stephen S. Khachikian, MD**

Albany Medical College Lions Eye Institute  
Albany, New York (USA)

**Jack T. Holladay, M.D., M.S.E.E., F.A.C.S**

Holladay LASIK Institute  
Vision Correction Surgery  
Bellaire Triangle Building  
Bellaire, Texas (USA)

**Mana Tehrani, MD**

Department of Ophthalmology,  
Johannes Gutenberg-University, Mainz  
Private practice - Constance, Germany

Oculus Optikgeräte GmbH

35549 Wetzlar

GERMANY

Tel. ++49-641-2005-0

Fax ++49-641-2005-295

[www.oculus.de](http://www.oculus.de)



# KERATOCONUS / ECTASIA DETECTION WITH THE OCULUS PENTACAM: Belin / Ambrósio Enhanced Ectasia Display

Michael W. Belin, MD, FACS • Stephen S. Khachikian, MD  
Albany, New York -U.S.A.

The early detection of ectatic disease is of paramount importance to the refractive surgeon. While measurements such as aberrometry and curvature can be used in evaluating a patient for ectatic disease, they are derivatives of elevation.<sup>1</sup> With subclinical disease, anterior curvature alone may not provide enough information to detect an early corneal abnormality. The goal of the **Belin / Ambrósio Enhanced Ectasia Display** is to combine elevation based and pachymetric corneal evaluation in an all inclusive display. This gives the clinician a global view of the structure of the cornea and allows the physician to quickly and effectively screen patients for ectatic disease. The combination of the pachymetric graphs and indices and the enhanced elevation maps provided by the **Belin / Ambrósio Enhanced Ectasia Display** have increased sensitivity and specificity in the screening of patients for ectasia.

## Elevation Based Topography

The basics and advantages of elevation based topography were discussed by Belin and Khachikian in an earlier issue of HIGHLIGHTS.<sup>2</sup> Elevation based Scheimpflug imaging has advantages over Placido based systems in that it allows for the measurement of both the anterior and posterior corneal surfaces and the computation of a complete pachymetric map.<sup>3</sup> This paper will concentrate on the use of the enhanced elevation map which makes up half of the new Keratoconus / Ectasia detection display (**Belin / Ambrósio Enhanced Ectasia Display**) available on the Oculus Pentacam (OCULUS Optikgerate GmbH, Wetzlar, Germany).

Elevation maps are typically viewed by comparing the data to some standard reference surface (shape). The reason for viewing elevation data in this format is that the actual raw elevation data lacks enough surface variability for an easy qualitative inspection that would allow the clinician to separate normal from abnormal corneas. By subtracting a

known shape, however, the differences or variance become highlighted or exaggerated (**Figure 1**). This method of depicting elevation data and the subtracted reference shapes commonly used (best-fit-sphere (BFS)), best-fit-ellipse, and the best-fit-toric ellipsoid) were first introduced by Dr. Belin in 1990 on the PAR CTS.<sup>4</sup>

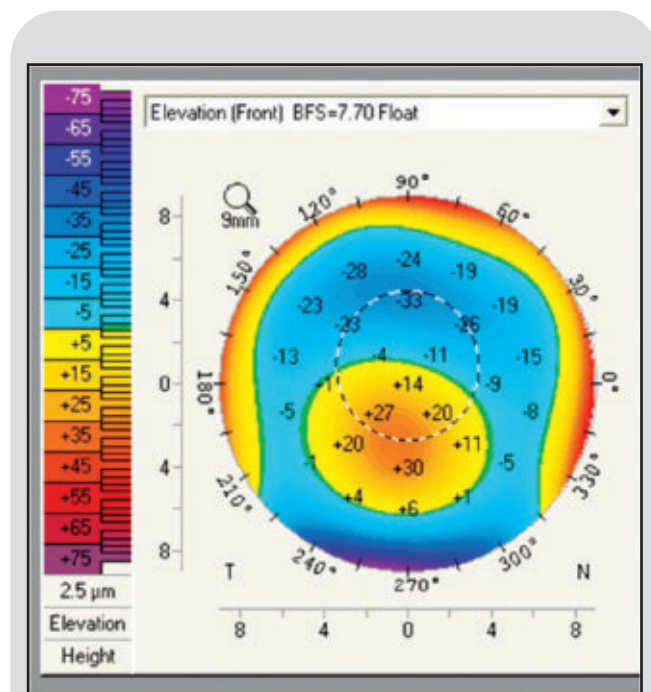


Figure 1. Anterior elevation map of a patient with keratoconus. The central island of elevation is clearly visible and it corresponds to the location of the cone. This would not be visible if one were not comparing raw data to a reference surface.



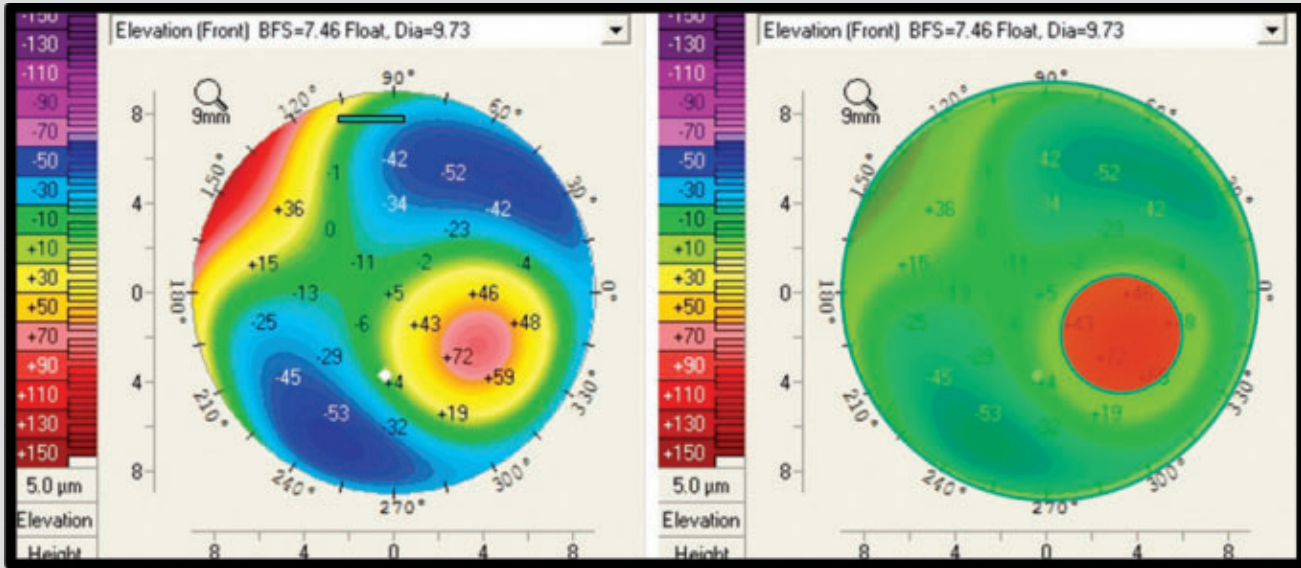


Figure 2. The image on the left shows a patient with Keratoconus and a large area of abnormal elevation. The image on the right reflects how this abnormal area of elevation (red circle) is excluded from the BFS calculation.

For refractive surgery screening and for most clinical situations, using a best-fit-sphere gives the most useful qualitative map (i.e. easiest to read and understand). Fitting a best-fit-sphere to the central 8.0 mm zone appears best for clinical interpretation. Since the normal eye is an aspherical, prolate surface the central 8.0 mm zone yields a reference surface that allows for subtle identification of both ectatic disorders and astigmatism.

### Enhanced Reference Surface

While the Best-Fit-Sphere (BFS) is qualitatively useful, the clinician typically assumes that the reference surface (the shape being subtracted) closely approximates a “normal” cornea. Some investigators, in the past, have attempted to compare individual corneas to some “average normal shape.” The problem here is that there is such variability in corneal shape that the “normal” or “average” shape does not represent a clinically useful reference surface for individual corneal evaluation. What is typically not appreciated is that the BFS will be influenced by any abnormal portion of the cornea. In the case of keratoconus or ectasia, the cone or apical protrusion will have the effect of steepening the BFS. This steepened BFS will actually minimize

the elevation difference between the apex of the cone and the BFS. We designed a new screening display (Belin / Ambrósio Enhanced Ectasia Display) to eliminate this problem.

Our goal was to design a reference surface that more closely approximates the individual’s normal cornea after excluding the conical or ectatic region. To do this, we identified a 4.0 mm optical zone centered on the thinnest portion of the cornea and excluded it from the reference shape calculation (**exclusion zone**). We calculated the new “**enhanced BFS**” by utilizing all the valid elevation data from within the 8.0 mm central cornea, and outside the exclusion zone (**Figure 2**). The resulting new reference surface (“**Enhanced BFS**”) closely approximates the more normal peripheral cornea and exaggerates any conical protrusion. In abnormal corneas the elevation map created when using the enhanced BFS will be significantly different from the map created using the standard BFS as your reference surface (**Figure 3**). This elevation difference is minimal in a normal cornea (**Figure 4**). With a conical cornea, excluding the 4.0 mm zone from the BFS calculation eliminates the cone or steep portion of the cornea and results in a significantly flatter BFS based more on the normal peripheral cornea. The resulting elevation maps show a significant difference as the conical portion of the cornea is now more pronounced (i.e.

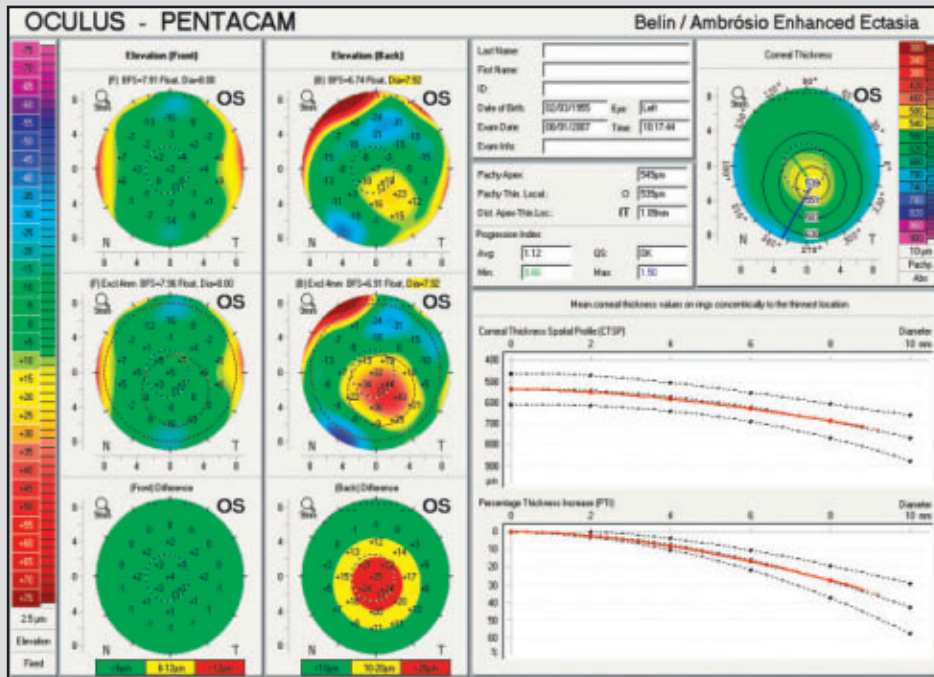
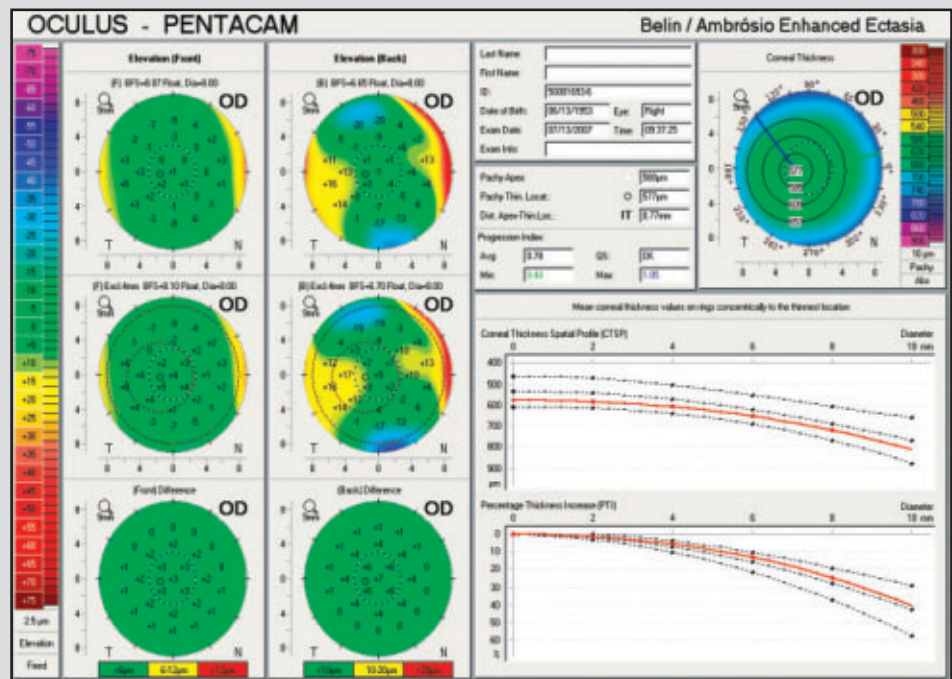


Figure 3. Belin/Ambrosio Enhanced Ectasia Display of a patient with early keratoconus. The baseline elevation maps (top) show the presence of a mild cone limited to the posterior cornea, while the exclusion map (middle) enhances the visibility of the abnormal cone. The change in elevation from the baseline to the exclusion map (bottom) shows a significant change on the posterior surface (red) and yet no significant change (green) on the anterior surface.

Figure 4. Belin/Ambrosio Enhanced Ectasia Display of a normal cornea. The baseline elevation maps (top) show normal corneal elevation map. The exclusion map (middle) has a similar appearance. The change in elevation from the baseline to the exclusion map (bottom) shows almost no change in elevation (green) on both anterior and posterior surfaces.





easier to identify) (Figure 3). The average changes in corneal elevation (when going from standard to enhanced BFS) were as follows:

Normal eyes showed an avg change in anterior apex and maximum elevation of  $1.86 \pm 1.9 \mu\text{m}$  and  $1.63 \pm 1.4 \mu\text{m}$ .

Keratoconus eyes showed anterior apex and maximum elevation changes of  $20.4 \pm 23.1 \mu\text{m}$  and  $20.9 \pm 21.9 \mu\text{m}$ .  
( $P < .0001$ ).

Posteriorly, normal eyes showed an average change in apex and maximum elevation of  $2.86 \pm 1.9 \mu\text{m}$  and  $2.27 \pm 1.1 \mu\text{m}$ .

Keratoconus eyes showed posterior apex and maximum elevation changes of  $39.9 \pm 38.1 \mu\text{m}$  and  $45.7 \pm 35.9 \mu\text{m}$ .  
( $P < .0001$ ).

This change (the elevation difference between the standard BFS and the "Enhanced" BFS) appears to have significant prognostic value as all normal eyes tested showed minimal change while eyes with keratoconus or ectasia showed a significant increase in elevation values (Figure 5).

### Elevation Display Interpretation

**Baseline Elevation Maps** - We can begin by looking at the left half of the **Belin /Ambrosio ectasia display (Figure 4)** where the elevation data of a normal eye is shown. The first two (upper) elevation maps (placed side by side) are the standard elevation maps of the cornea off the standard best fit sphere. This map is displayed for the front surface (left map) and back surface (right map) of the cornea. The radius of curvature of the best fit sphere (BFS) in millimeters and the diameter of the zone used to compute the BFS is noted above each map. In this sample map (Figure 4) the radius of curvature of the Best Fit Sphere for the front surface of the cornea is 8.07 mm and the radius of curvature of the BFS for the back surface of the cornea is 6.65. "Float" describes the positioning of the reference surface relative to the corneal surface. The last number above the elevation

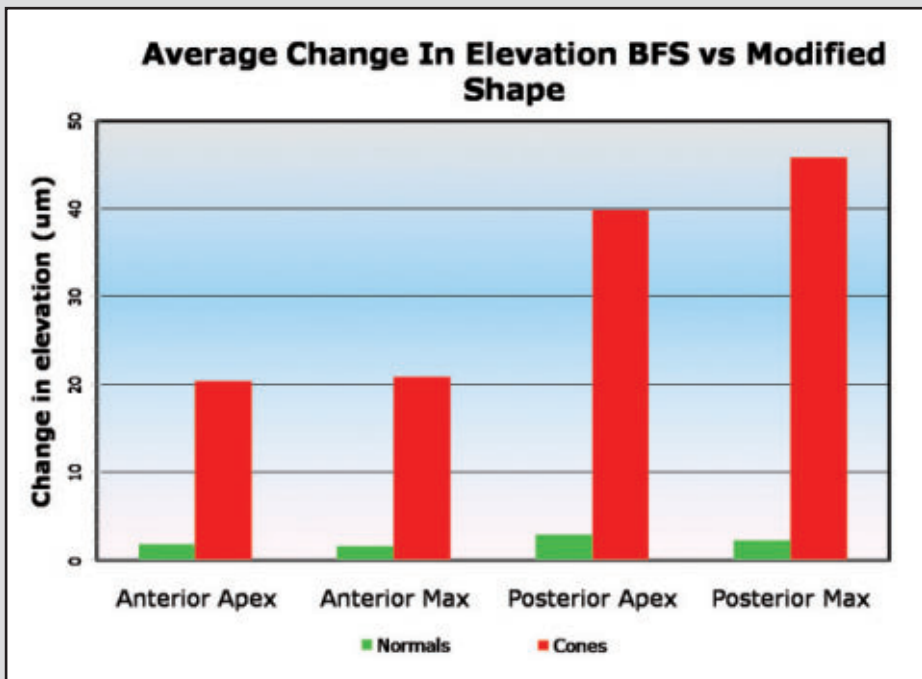


Figure 5. Bar graph showing the relative change in elevation for normal eyes (green) and keratoconics (red) when comparing elevation measured with the baseline BFS and the enhanced BFS.



map is the diameter of the circle (in millimeters) centered on the corneal apex inside of which valid corneal data is taken to compute the BFS. For the Belin / Ambrosio display this is fixed at 8.0 mm if there is adequate coverage and no extrapolated data. A poor pentacam image will contain less valid data and therefore the diameter of the circle from which data is taken is smaller. To the left of the elevation map is the number 9 mm. This is the size of the cornea being displayed. To the right of the map is the eye being examined, OD or OS. Looking at the color scale of the map itself, warm colors represent areas of the cornea that are above the BFS, and cool colors represent areas of the cornea below the BFS.

*“The goal of the software is to assist the refractive surgeon in identifying those patients who may be at risk for post-operative ectasia and/or to assist in the identification of early or subclinical keratoconus.”*

**Exclusion Maps** - Immediately below the standard anterior and posterior elevation maps are the anterior and posterior exclusion maps. These are enhanced elevation maps, which display the same elevation data as the baseline maps, but the reference surface is now the “enhanced BFS” rather than the standard BFS. In these maps (both anterior and posterior) the best-fit sphere is calculated using all the raw elevation data located outside a 4mm circle centered on the thinnest point of the cornea. This area of excluded data is called the exclusion zone and the map is an exclusion map. The location of the exclusion zone is indicated by a 4mm red circle and cannot be modified.

This “exclusion map” may be significantly different from the baseline elevation map (**Figure 3**), or it may be very similar (**Figure 4**), depending on the relative impact the 4 mm exclusion zone made to the original (standard) BFS computation. As noted above, the change in BFS is typically minor for normal eyes (8.07 to 8.10 for the anterior cornea and 6.65 to 6.70 for the posterior cornea (**Figure 4**)) and more significant for eyes with ectatic changes (6.66 to 6.80 for the posterior cornea in (**Figure 3**)).

The bottom 2 maps are difference maps showing the relative change in elevation from the baseline elevation map to the exclusion map. The bottom maps contain only 3 colors, each one corresponding to the amount of elevation change that occurs when moving between the baseline elevation map and

the exclusion map. The green on the difference map represents a change in elevation (from the baseline to the exclusion map) of less than 6 microns on the front surface and 10 microns on the back surface of the cornea. These values are typically within the range seen in normal eyes, as in this example. Red would represent areas where the elevation difference between the 2 maps is  $\geq 12$  microns anteriorly or 20 microns posteriorly and are the magnitude typically seen in eyes with known keratoconus. Yellow areas represent a change between 6 and 12 microns for the front surface and 10 to 20 microns for the back surface. These eyes fall in the suspicious or suspect zone. In these examples the difference maps are both all green in the normal eye (**Figure 4**) and green for the anterior surface but strongly positive (red) for the posterior surface for the eye with ectatic changes more significant on the posterior corneal surface (**Figure 3**).

## Conclusion

The **Belin / Ambrósio Enhanced Ectasia Display** is the first comprehensive refractive surgical screening tool to be fully elevation based. The goal of the software is to assist the refractive surgeon in identifying those patients who may be at risk for post-operative ectasia and/or to assist in the identification of early or subclinical keratoconus. By utilizing information from both the anterior and posterior corneal surfaces, as well as full pachymetric data it is hoped to have increased sensitivity without the false positive rates typically associated with curvature based programs.

## REFERENCES

1. Belin MW, Litoff D, Strods SJ, et al: The PAR Technology Corneal Topography System. *Refract Corneal Surg* 8:88-96, 1992.
2. Belin MW, Khachikian SS. Corneal diagnosis and evaluation with the OCULUS Pentacam. *Highlights of Ophthalmology*. 2007; 35:5-8.
3. Ciolino JB, Khachikian SS, Cortese MJ, Belin MW. Long-term stability of the posterior cornea after Laser In Situ Keratomileusis. *J Cataract Refract Surg*. 2007; 33:1366-70.
4. Belin MW, Litoff D, Strods SJ, et al: The PAR Technology Corneal Topography System. *Refract Corneal Surg*. 1992; 8:88-96.

# APPLICATION OF PENTACAM IN ANTERIOR CHAMBER MEASUREMENTS FOR PHAKIC IOL SURGERY

**Mana Tehrani, MD**  
**Constance, Germany**

Phakic intraocular lenses have been established as an effective and safe surgical option for the correction of myopia, hyperopia and astigmatism. One of the current available phakic IOLs is the iris-fixated lens for correction of refractive errors.

However performing refractive surgery on healthy eyes demands high standards in precise patients selection and pre-operative diagnostic examinations. Of major interest in phakic IOL implantation remains if safe distances from the phakic IOL to crucial tissues such as corneal endothelium or crystalline lens can be respected postoperatively. The lack of an accurate anterior segment analysis and predication of pIOL position after surgery encouraged us to develop a software module applicable to the new high resolution HR Pentacam.

The Pentacam HR (OCULUS, Wetzlar, Germany) images the anterior segment of the eye by a rotating Scheimpflug camera non-contact measurement. Two types of the device are available on market; the newer one is the Pentacam HR, offering an increased image resolution. The rotating Scheimpflug camera provides a series of 50 Scheimpflug images in 2 seconds, showing the anterior segment of the eye from the anterior cornea surface down to the posterior surface of the crystalline lens. Out of each of these images 2760 true elevation points are extracted by the software, obtaining 138.000 true elevation points for each surface, including the center of the cornea. The software generates a 3D-model of each surface as a basis for corneal topographic and anterior chamber analysis.

The new Pentacam pIOL-software module simulates the positioning of a pIOL in the anterior chamber 3D-model and

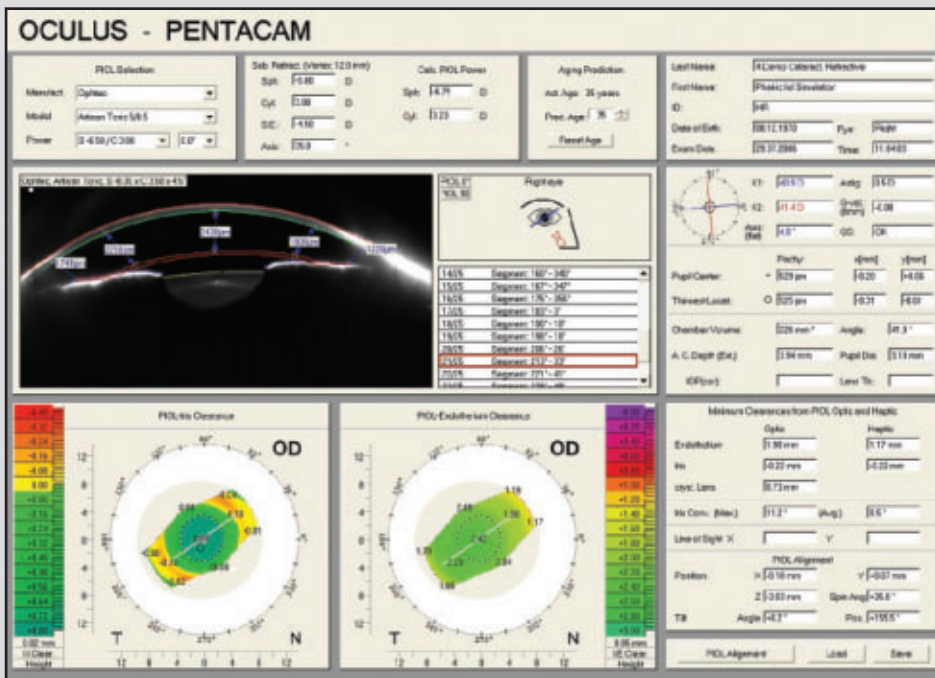


Figure 1. Preoperative anterior chamber image with simulation of postoperative pIOL position.



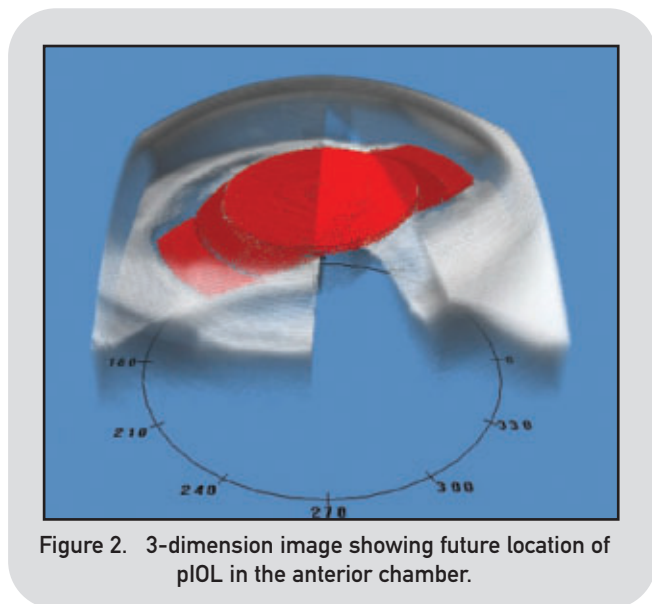


Figure 2. 3-dimension image showing future location of pIOL in the anterior chamber.

makes it visual to the surgeon before surgery. After entering the patients refraction in the module the software can choose the required pIOL model out of the integrated lens database. This pIOL can then be projected in the patients anterior chamber that has been obtained before by regular Scheimpflug measurement. The pIOL is automatically aligned on the iris surface, centered on pupil after being selected from a lens data base. In every single taken Scheimpflug image the outlines of the simulated implant are drawn. Moreover from each surface point of the pIOL the distances to adjacent eye structures are calculated three dimensionally by the software, which results in real minimum values. These distances are presented both in colour maps which show every point of the implant in top view and as minimum space values for critical areas of the pIOL. Besides the colour maps represent the actual simulated position in the X-Y-plane relative to the apex and the pupil. The surgeon carries out the alignment of the pIOL by drag and drop in the colour maps in every direction. With the help of online refreshed distance values and images the optimum lens position and axis alignment will be defined and the compliance of the minimum distances is supervised. While the pIOL is moved in X-Y-direction or axis angle is changed the software assists this process by always aligning it on the iris surface. Final corrections in height and tilt will then be carried out by the surgeon for compensating incorrect positioning caused by irregular iris spots. Beside projection of the selected IOL power/type in the patient's anterior chamber, the software program gives exact values in mm about the minimal distances between endothelium to IOL optic and haptic, the minimal distances from the IOL backside to the iris and the minimal distance between the backside of the IOL and the crys-

talline lens. In addition distances from the IOL to other tissues can be read from any point of the implant by going with the cursor on the specific point of the implant.

In a clinical study performed at the Department of Ophthalmology at the University of Mainz, Germany 44 eyes of 23 patients were included. The average age valued 38 years (range, 24-61). The implanted pIOL power ranged from +11 to -22 D with a average power of -8,70 D. 17 eyes received the foldable model (Artiflex, Ophtec, Groningen; Veriflex, AMO, Santa Ana, USA), 13 eyes the rigid PMMA Model (8 myopic, 5 hyperopic model).


One day before planned surgery a Pentacam HR investigation using the novel pIOL software module was performed in all cases. One month after surgery a second investigation was performed to compare preoperative simulation values with actual postoperative distance values. A mean deviation from simulation to postoperative values were detected of 18  $\mu\text{m}$  for the distance central pIOL optic to corneal endothelium, 56  $\mu\text{m}$  for the distance peripheral optic to corneal endothelium and 25  $\mu\text{m}$  for the distance posterior pIOL optic to anterior surface of crystalline lens. Finally a mean deviation between simulation and postoperative position of 31  $\mu\text{m}$  for the distance pIOL haptic to corneal endothelium could be evaluated.

### Additional Features

The changes in anterior segment dimension through aging process were also considered when developing this module. The annual decrease in anterior chamber depth is also calculated. This decreasing anterior chamber depth can be predicted by the software for a selected patient's age to avoid future complications. The aging tool can predict the pIOL position up to 30 years in advance.

Another important feature under development is the option to simulate the toric models (Model A and B) where the surgeon can decide which model would fit better in the patients anterior chamber.

Analysis of anterior chamber dimensions via Scheimpflug imaging is an important step to ensure that sufficient distances between critical tissues are respected postoperatively. In addition, simulation of the required iris-fixated lens model (including complete biometric data such as thickness, height etc.) preoperatively during patients selection progress represents a powerful step toward increasing safety of this surgical option. Especially patients with irregular iris formation, poor central and peripheral anterior chamber dimensions can benefit from these additional features in the Pentacam. Moreover the image can be shown to the patient illustrating why he is not a good candidate for iris-fixated IOL implantation.



# HOLLADAY REPORT ON THE PENTACAM

**Jack Holladay, MD, MSEE, FACS**  
 Bellaire, Texas - U.S.A.

The Pentacam is the latest technology in Scheimpflug imaging. It is manufactured by Oculus Optikgeräte GmbH(Wetzlar, Germany) and differs fundamentally from the Orbscan (Bausch & Lomb, Rochester, NY) by the way in which it takes image slices of the cornea. The Orbscan takes vertical image slices that are separated from one another and have no common point. Thus, the Orbscan cannot re-register for any eye movement that occurs while it is capturing the images. The Pentacam maintains the central point (usually close to the thinnest point) of each meridian in the sample images (**Figure 1**). Thus, during the reconstruction of the image, the software can re-register these central points and eliminate the eye movement. The second improvement is the resolution of the camera. Just like digital cameras, the megapixels used in the latest high density imaging are much greater than cameras just a few years ago. These two features make the Pentacam’s measurements significantly more accurate than the prior instruments.

The Scheimpflug images also have a density graph to the right of the image, which allows the physician to quantify visu-

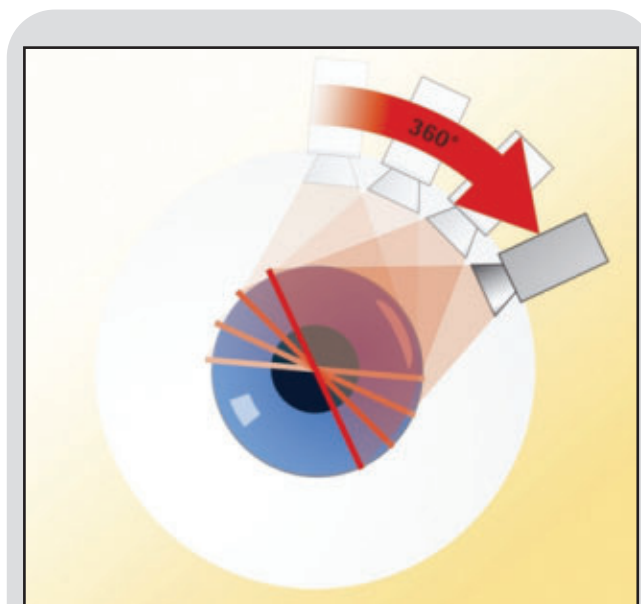


Figure 1. During reconstruction of the image, Pentacam maintains the central point of each meridian.

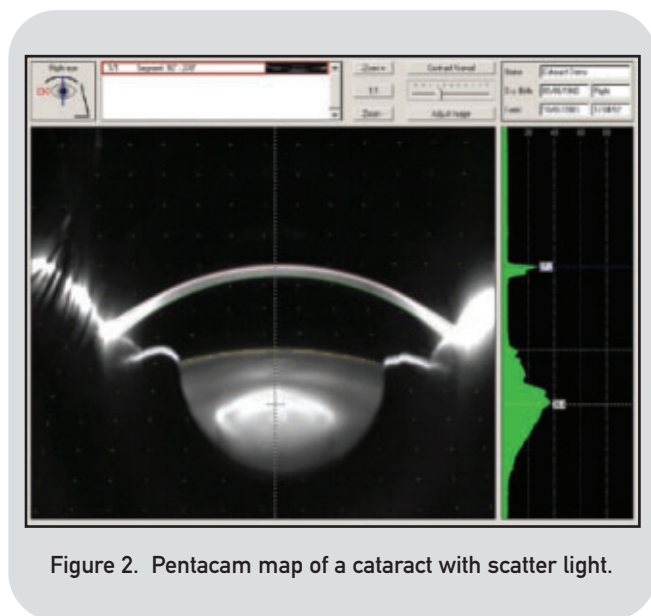


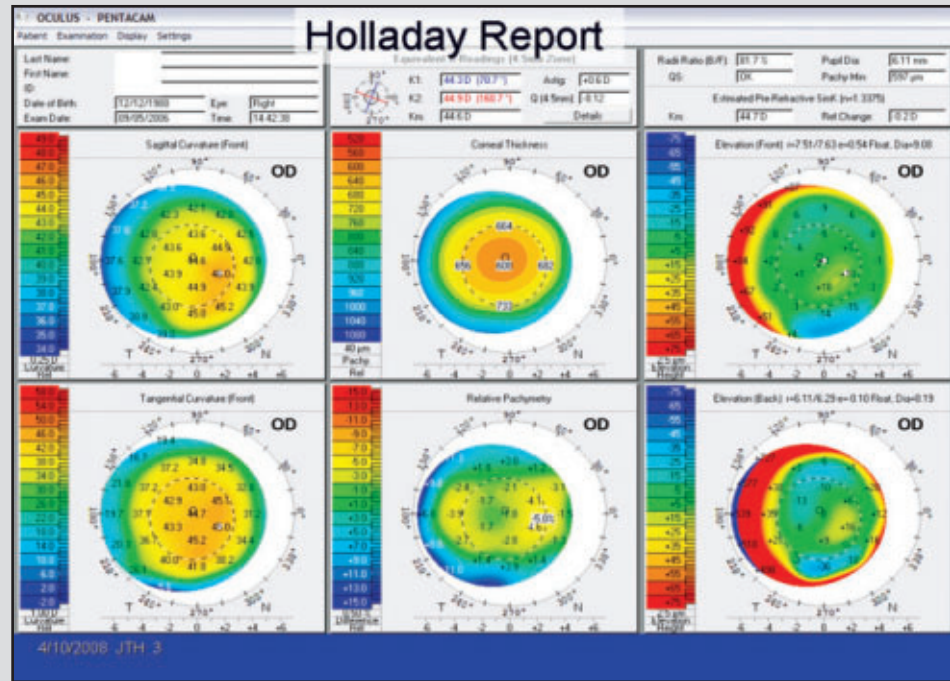
Figure 2. Pentacam map of a cataract with scatter light.

al disturbances in the media. For example, the map of a cataract (**Figure 2**) shows the opacities that scatter light and degrade vision. The clinician can show these maps to the patient, and document the changes that are occurring to the patient’s crystalline lens in his chart.

The Holladay Report contains 2 displays. The first page is shown in (**Figure 3**) and includes 6 maps. These 6 maps have been chosen because they provide the clinician with all of the information necessary to evaluate a patient in almost all cases. The second page (**Figure 4**) is displayed when the ‘detail’ button is clicked and displays additional information about the cornea which is primarily used for IOL calculations after refractive surgery, which will be discussed in detail in the section below.

I like to include curvature maps in my preoperative screening. It is true that curvature maps are relative to the center of the earth (primary corneal radius of curvature), and that height maps are relative to a vertex point on the cornea. The Pentacam uses

Figure 3. First page of the Holladay Report, which includes six maps to provide the clinician all the necessary information to evaluate a patient.



a sagittal drop-down map to reference a fixed physical point on the surface of the cornea for elevation maps. When using a curvature map, you calculate a radius and then determine the major center of the radius of the curvature (a calculated point). If the machine does not calculate the right point, or if the patient is not lined up, then the radius-of-curvature calculation will be off. The Pentacam has an alignment device that prevents decentration.

In Figure 3, in the upper left hand corner is the patient's demographic information. The upper center box are the Equivalent K-readings (EKR) for a 4.5 mm zone that may be used for IOL calculations. The upper right hand corner is what the program calculates the K's would have been before refractive surgery. In this case, since there has been no surgery, the values are almost identical to the EKR values.

On the middle row of Maps are the Sagittal Front, Pachymetry and Front Elevation Maps. The Sagittal Front or Axial Power Map is the most common map used in topography and represents the axial power of the cornea at all points. The Pachymetry Map shows the thickness at all points in the cornea and is especially helpful for the central corneal thickness. The Front/Back Elevation Map shows the height of the anterior/posterior cornea relative to the Best Fit Toric Ellipsoid. Although a sphere may be used for the fit, a toric ellipsoid is nearer to the shape of the normal cornea. Because the cornea is normally ellipsoid, if a sphere is used the center is always above the sphere and the periphery is always below (Figure 4). This makes it difficult to

give normal values because it depends on the shape of the cornea. Also, if astigmatism is present, a 'Band' will appear across the center because the steeper meridian will be below the reference sphere and the flatter meridian above. When a toric ellipsoid is used the Band disappears because the reference surface is toric and because the ellipsoid is used the central vaulting

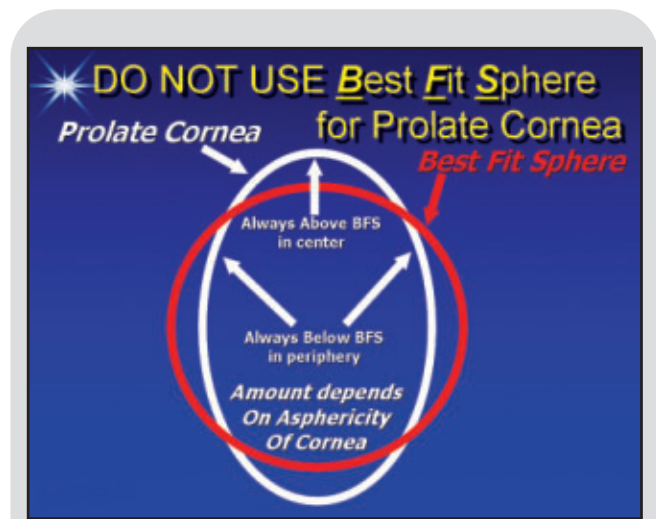


Figure 4. Because the cornea is normally ellipsoid, if a sphere is used, the center is always above the sphere and the periphery is always below.



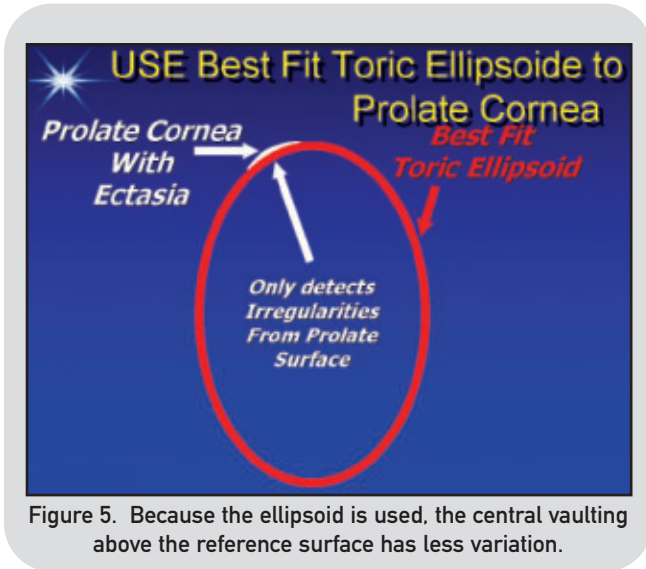


Figure 5. Because the ellipsoid is used, the central vaulting above the reference surface has less variation.

above the reference surface has less variation (**Figure 5**). The Tangential Map is the most sensitive for determining the geometry of the cornea. Unlike the Sagittal Map, the Tangential Map Curvatures are relative to the surface, not the axial center of the surface. A simple analogy would be to consider the earth a sphere with a radius of 8,000 miles with a hemisphere on the surface that was 6 miles high (Mount Everest). On the Sagittal Map, the radius would measure 8,000 and 8,006, since the center of the earth is the reference, almost no difference is detected. On the Tangential Map, the Earth would be 8,000 miles, but the hemisphere radius would be 6 miles, so a very large difference is detected. The Tangential Map is always the most sensitive measure of the geometric surface. Because of this property the Tangential Map shows the exact location of the 'nipple' of the cone. Notice the steepest part is at 330 degrees approximately 2 mm from the center (white diamond). The Relative Pachymetry Map gives the thickness of the cornea at that point relative to the normal thickness at that point as a percentage. A normal Map would be 0% at all points. Even though the cornea gets thicker as we move to the periphery, if the patients thickness increases normally, the Map still appears green (0.0%).

## Detecting Forme Fruste Keratoconus

### Strategy

In Figure 3, we see that the Relative Thinnest Point is -5.0% thinner than it should be at that point. Note that this point is at the same location as the nipple on the Tangential Map. Finally, the Back Elevation Map using the Best Fit Toric Ellipsoid, has a yellow spot that is +16 microns above the Reference Toric

Ellipsoid, also at the same 'hot spot' as the Tangential and Relative Pachymetry Map. Note that this point on the Normal Pachymetry Map does not show up because the cornea is still thinnest centrally, so the Relative Thickness is obscured. It is of interest to note that epithelium of the corneal anterior surface thins over the nipple, reducing the sensitivity of the diagnosis from the front surface alone. In this case the anterior surface is only 10 microns above the Reference Surface (not 16 microns as on the Back Elevation). Normal epithelial cells are 6 to 8 microns thick and there are usually 6 to 8 layers of epithelial cells. The epithelium is ~ 1 epithelial cell thinner over the 'nipple'.

### Summary

The strategy is that when the 'hot spot' on the Tangential Map, Relative Pachymetry Map and Back Elevation Map using the Toric Ellipsoid are all at the same point, the diagnosis of Forme Fruste Keratoconus is confirmed.

In our experience:

- Relative Pachymetry Measurements that exceed -3.0% are significant
- Elevations above 15 microns above the Toric Ellipsoid on the Back Elevation Map are significant.
- Nipple on tangential map is red and usually above 48 D.

## Equivalent K-Readings (EKRs) IOL Calculation for Patients After Refractive Surgery

When performing IOL calculations, you cannot use height data, but must use curvature maps to determine the power of the cornea. Topography does not supply back surface power. Therefore, the variation in back surface power among the human population means that K readings that may appear the same between multiple patients are not exactly the same, because their posterior curvatures and net powers may be different.

For calculating the EKR after LASIK, we first measured 100 consecutive refractive surgery patients who were between 20 and 30 years old with the Pentacam pre- and postoperatively. Using the historical method, we were able to calculate what their K-readings should have been postoperatively. The correlation between the calculated K-reading and the Pentacam measures EKR was 96%, with 0.56 D standard deviation. Thus, we were able to predict patients' postoperative refractive powers within 0.56D. In a second study, 41 RK eyes were evaluated. These patients underwent cataract surgery and ~ 6 weeks post op, the refraction was measured and the Pentacam EKR was measured.



Using the post op refraction, the K-reading was back-calculated using the Holladay IOL Consultant Software. The correlation of the back-calculated K-reading and the measured EKR was 90% with a standard deviation of 0.94 D. In these studies (J. T. Holladay, MD and Warren Hill, MD) using LASIK, PRK an RK patients, the best correlation was found while using the EKR's over a 4.5mm zone.

More and more patients who have received a LASIK, PRK or RK treatment in the past are developing now cataract. But often we have no information about the pre-op K-readings and therefore the eg. double-K-method does not work to calculate the IOL. This problem is well known and several methods have been tried to get proper K-readings for the calculation of the IOL. Placido based topographers for example are calculating the refractive power of the cornea with the approximation that the radii ratio between back/front of the cornea is 82% and constant. This leads to an overall average corneal refractive index of  $n=1.3375$ . This is correct for untreated eyes but after any surface alteration the radii ratio changes. For myopic treatments it decreases and for hyperopic treatments it increases. Therefore we have to consider the anterior and posterior curvature to calculate the true corneal power. The specific refractive indices for cornea and for aqueous have to be used in order to convert curvature into refractive power. Another fact is that Placido based topographers always have a blind spot in the center and this area is interpolated assuming a central steepening. This is correct for untreated eyes but after myopic treatments it is vice

versa. This causes in wrong curvature and wrong refractive central corneal power to be reported. But it is essential to measure the center for accurate corneal measurement especially for the K-readings. The Pentacam measures though the rotating scan especially this area very precisely. The Equivalent Keratometer Readings, EKR's consider all these effects. Additionally they are calculated with reference to the pupillary center, not vertex normal (the actual center of the measurement).

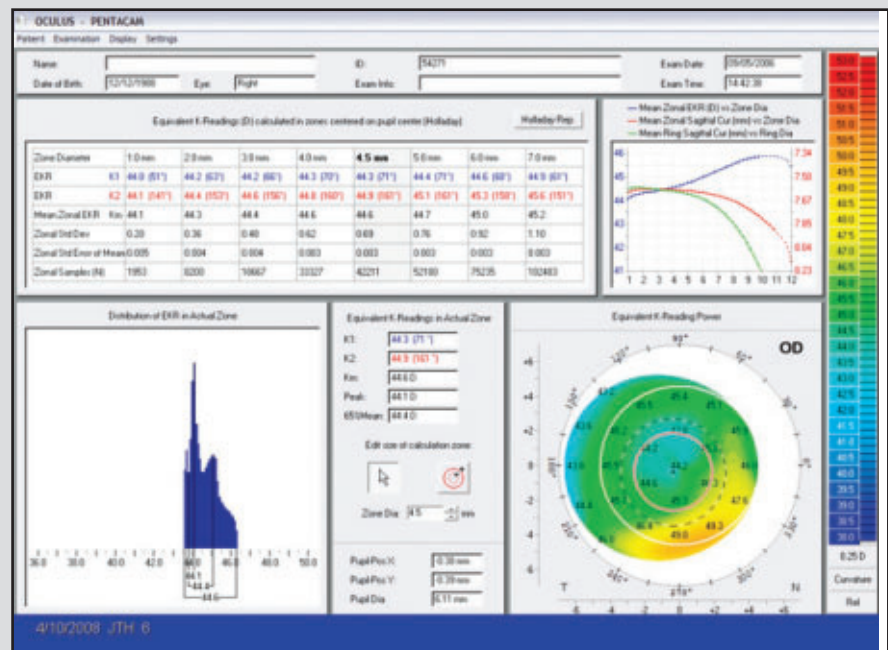
### Details of the Holladay Report

By clicking the 'detail' button on the 1st page (Figure 3), a second page is displayed (Figure 6). The table in the upper left displays the EKR's in different zones around the pupil center. Especially for patients with very big or small pupil diameters the EKR's can be selected in accordance. The diagram in the lower left displays the refractive power distribution of the EKR's in the selected zone, here the 4.5mm. The example shows a clear peak. This corresponds well with the upper right diagram which shows the progression of:

- mean zonal EKR vs. zone diameter in blue
- mean zonal sagittal curvature vs. zone diameter in red
- mean ring sagittal curvature vs ring diameter in green.

The red and the green graph are parallel up to the 4mm - 4.5mm zone around the pupil center. Because of the small range EKR's and the clear high peak, a good post-operative outcome can be expected.

Figure 6. Second page of the Holladay Report.





# 14 New Advances and Technology with Pentacam



In Figures 7 and 8 is a patient who has had LASIK. In Figure 8, the refractive power distribution diagram displays a wide range of refractive power and no clear peak. The diagram in the upper right hand side shows that the red and green graphs are not parallel. The 'knee' in green shows the edge of the optical

zone and the beginning of the transition zone. The wide variation in corneal power makes the exact EKR power difficult to predict exactly.

In Figures 9 and 10 is a patient that has had RK. In Figure 10, the refractive power distribution ranges from 32 to 45 D in power

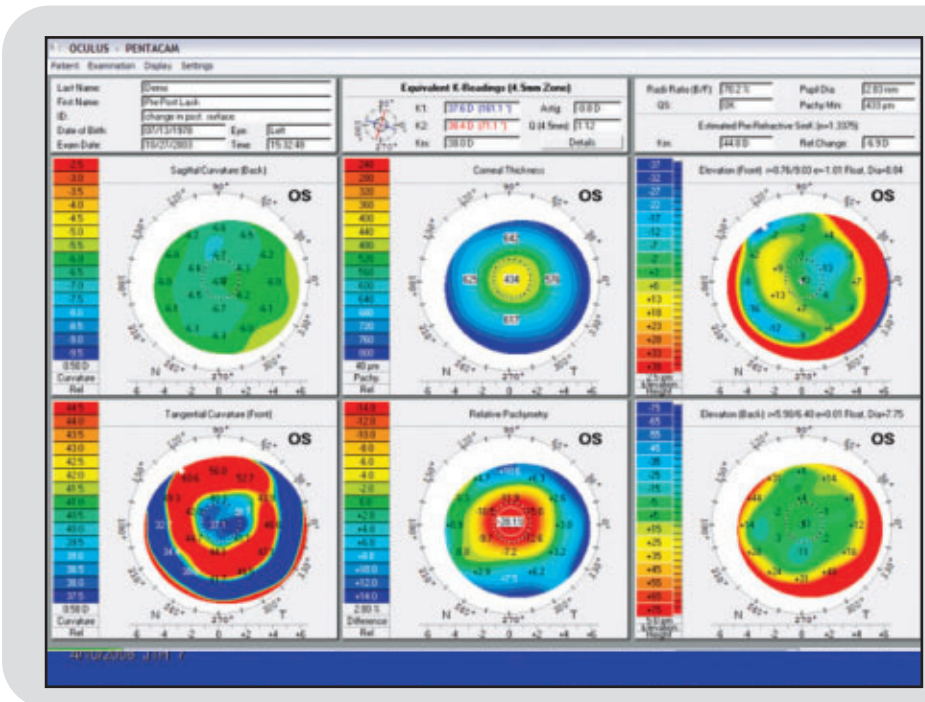
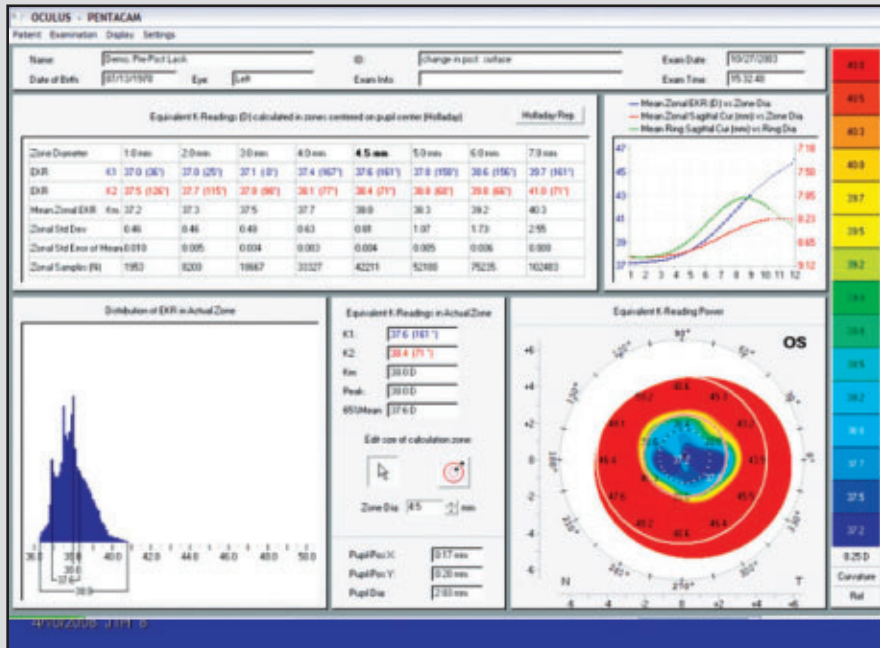


Figure 7. Patient who has had a LASIK procedure.

Figure 8. Same patient than figure 7. Please notice that the refractive power distribution diagram displays a wide range of refractive power.





within the 4.5 mm zone. The 'knee' in the green is even sharper than that of the LASIK patient and the EKR distribution is so variable (13 D), that the estimation of corneal power is even more inexact. In the cases with large variation in corneal power over the optical zone, the historical method should still be calculated when avail-

able. Also, in RK patients with a Standard Deviation of 0.94 D, it means that 5% of patients will be outside of a 1.84 D error (2 std dev). One should always target for myopia in these patients (-1.0 D or more), to assure they have some useable vision without glasses.

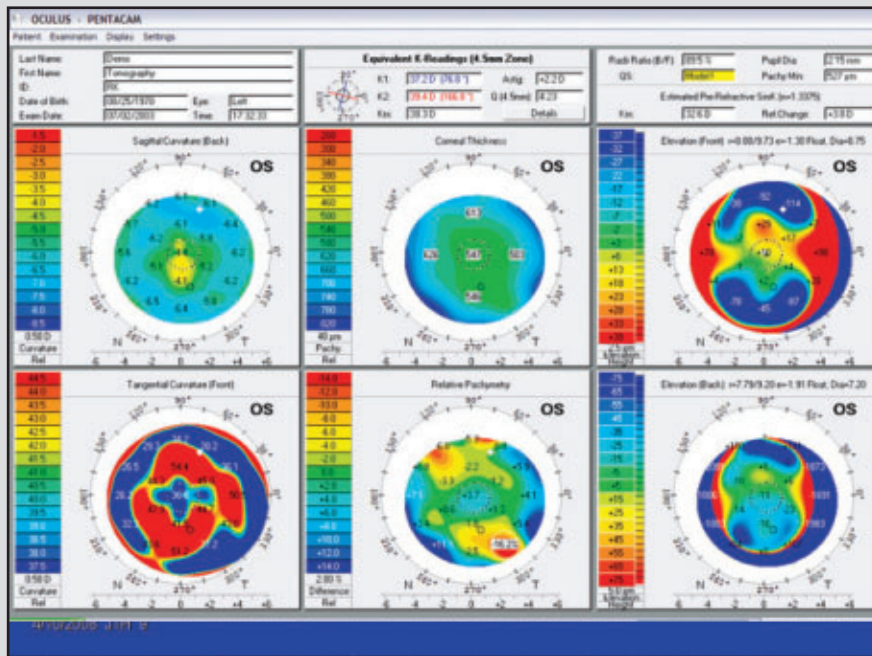
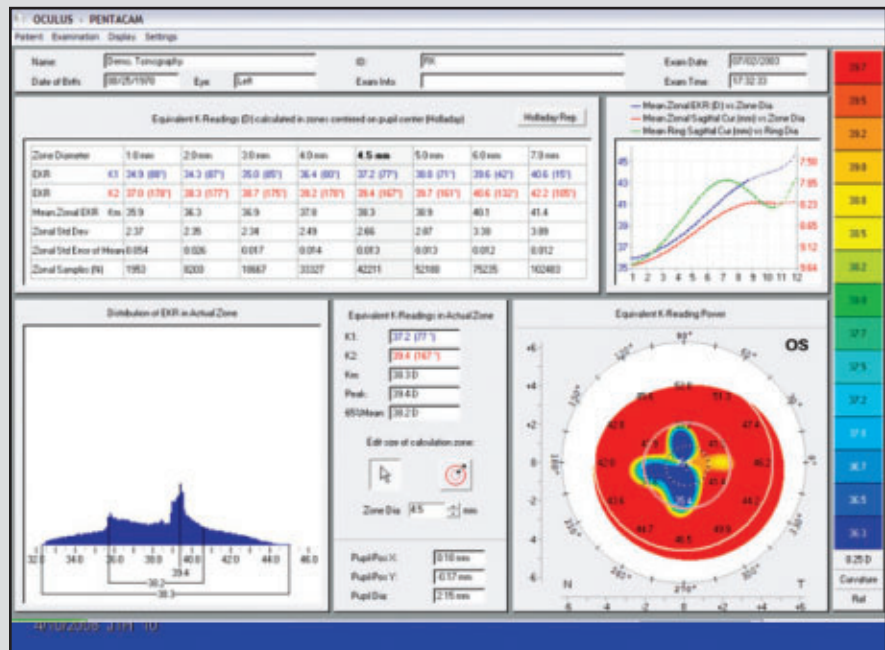


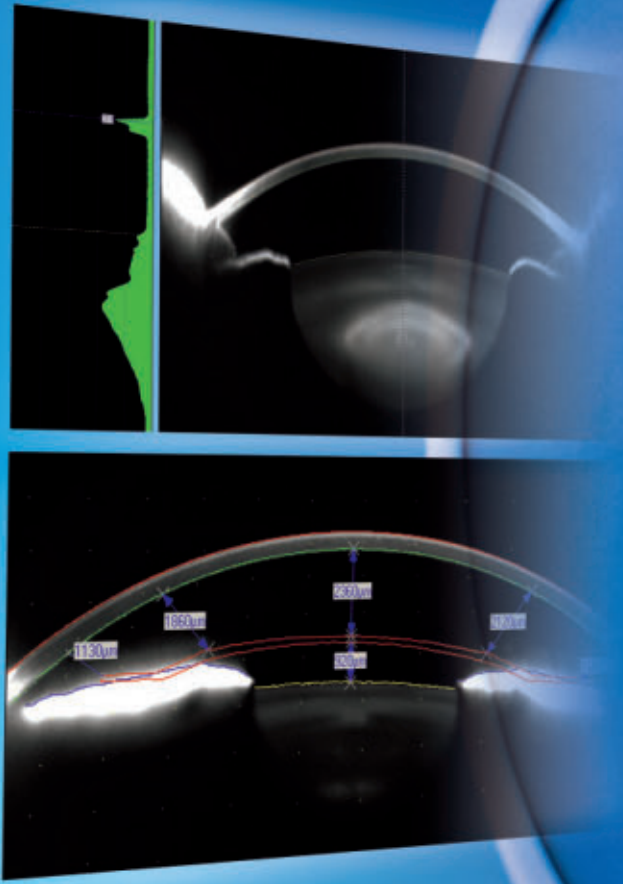
Figure 9. Patient who has had an RK surgery.

Figure 10. Same patient than figure 9. Please note that the refractive power distribution ranges from 32 to 45 D.





3D phakic IOL simulation software  
including aging prediction



# Holladay Report – IOL calculation for post-refractive patients

## The Oculus Pentacam HR

- Complete anterior imaging and analysing
- Anterior and posterior topography
- Manual white to white analysis
- Complete crystalline lens imaging
- Automatic release for high user independence
- 3D phakic IOL simulation software (optional)