



Author: Stefan Schwarz FAO,  
MCOptom, Diplomate in Cornea,  
Contact Lenses and Refractive Technologies  
Hildesheim, Germany

## Alarming high myopia managed with multi focal contact lenses

The increasing myopia prevalence opens a new field for optometry. Educating parents and kids about risk factors, monitoring regimen and treatment options is an ethical responsibility as well as a new task for preventive optometry to identify those at risk for developing axial elongation along with severe eye health issues later in life.

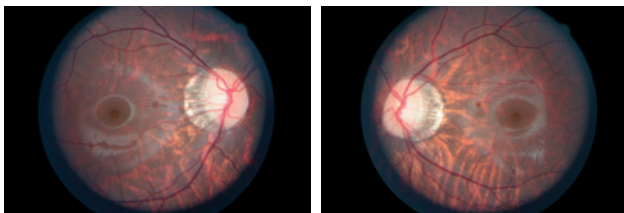
First patient visit was in Oct 2019. RR was a than 12-year-old boy of Amerindian ethnicity. Both parents were myopic and he was diagnosed with myopia when he was five years of age. Due to his near tasks at school but also due to his excessive gaming behavior pattern he was exposed to near work at least six to eight hours per day. He was fitted in monthly soft contact lenses by his ECP and was referred to us for counselling because he showed myopic progression of approximately one diopter/year since he was five years old.

His entering uncorrected visual acuity was finger counting OU (oculus uterque).

Refraction values were

	Sph	Cyl	Ax	VA
OD	-10.75 D	-0.50 D	71°	20/25
OS	-11.75 D	-0.25 D	15°	20/25

Fundus images showed myopic changes OU



Myopia Master measurements in Sept 2019 showed an axial length and refractive error of

	Axial length	Sph. Equivalent
OD	25.70 mm	-10.53 D
OS	25.99 mm	-12.15 D

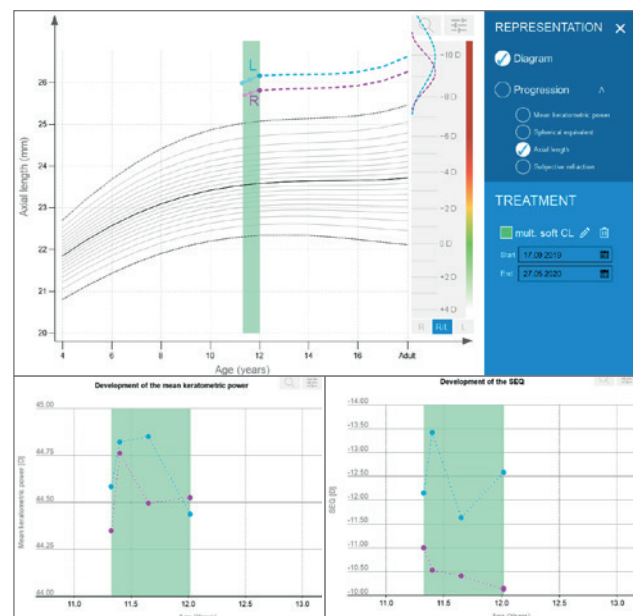
We fitted the patient in soft multifocal lenses for the treatment of progressive myopia (Galifa Scalia Myo 3) with a center distance design and agreed to monitor myopia progression every three month. Our advice was to avoid near work as much as possible.

At follow-up on May 2020, he reported that he was able to wear the contact lenses on a regular daily basis without side effects and that he had reduced his gaming activities significantly. Visual acuity with contact lenses was 20/25 OU.

Myopia Master readings in May 2020 were

	Axial length	Sph. Equivalent
OD	25.82 mm	-10.15 D
OS	26.17 mm	-11.04 D

The Myopia Master trend analysis shows only small progression regarding axial length. Refraction and keratometry is stable.



### Conclusion

This case demonstrates that it is possible to reduce myopic progression significantly by choosing adequate treatment options along with patient education about risk factors for progressive myopia. Consecutive follow-up examinations with axial length and refractive error measurements are crucial to ensure safety and treatment success.